

**AL-FARABI KAZAKH NATIONAL UNIVERSITY**  
**Medicine and Health Care Faculty**  
**Higher School of Medicine**  
**Department of Fundamental Medicine**

**Final exam program of**  
Morphology and human physiology of human body (12 credits)  
**Spring semester, academic year 2023-2024**

**Topics for the final exam**

1. Anatomical Position. Anatomical Planes. Directional Terms. Major Body Regions (Axial and Appendicular Region) Body Cavities and Membranes. Organ Systems
2. The Structure and functions of the skin. Structure and functions of the Cutaneous Glands, dermal circulation;
3. Bone Development. Physiology of Osseous Tissue. Bone Disorders
4. Cranial Bones. Facial Bones
5. General Features of the Vertebral Column. General Structure of a Vertebra. Intervertebral Discs. Regional Characteristics of Vertebrae. Thoracic Cage
6. The Upper Limb and Lower Limb
7. The Pelvic Girdle. The Lower Limb
8. Joints and Their Classification; Jaw and knee joints.
  1. The Functions of Muscles; General Aspects of Muscle Anatomy.
  2. Physiology of Skeletal Muscle, Cardiac muscle and smooth muscle.
  3. Muscles of the head and neck
  4. Muscles of the Anterior Abdominal Wall; Muscles of the Pelvic Floor; Muscles of the Back. Muscles of Respiration. Muscles Acting on the Hip and Femur, Muscles Acting on the Knee and Leg. Muscles Acting on the Foot, Intrinsic Muscles of the Foot
  5. Muscles Acting on the Shoulder and Arm; Muscles Acting on the Forearm, the Wrist and Hand
  6. Whole-Muscle Contraction; Muscle metabolism
  7. Introduction, Blood Types. Erythrocytes. Leukocytes.
  8. Platelets and Hemostasis, The Control of Bleeding.
  9. Overview of the Cardiovascular System. Gross Anatomy of the heart
  10. Cardiac Muscle and the Cardiac Conduction System; Electrical and Contractile Activity of the Heart.
  11. Cardiac cycle and heart sound; Cardiac output
  12. General Anatomy of the Blood Vessels; Capillary Exchange; Physiology of Circulation
  13. Circulatory Routes and Blood Vessels of Axial and Appendicular Region
  14. The lymphatic and immune system.
  15. General Anatomy of the Respiratory System
  16. Pulmonary Ventilation
  17. Gas Exchange and Transport
  18. Anatomy and functions of the Urinary System
  19. Urine Formation I: Glomerular Filtration, Tubular Reabsorption and Secretion Water Conservation
  20. Fluid, Electrolyte and Acid Base Balance
  21. Nutrition; Metabolic States and Metabolic Rate
  22. General Anatomy and Digestive Processes; The Mouth Through Esophagus; The Stomach; The Liver, Gallbladder, and Pancreas; The Small Intestine and Large Intestine
  23. Chemical Digestion and Absorption
  24. Overview of the Nervous System; The basic structure and Physiology of Neurons.\
  25. The Spinal Cord ; The Spinal nerves; Somatic Reflexes

26. Overview of the brain. Principal Divisions of the Brain
27. Integrative functions of the brain;
28. The Cranial Nerves
29. The Autonomic Nervous System
30. Overview of the Endocrine System ; Hormones and Their Actions; The Hypothalamus and Pituitary Gland ;Other Endocrine Glands
31. Properties and Types of Sensory Receptors;The General Senses; The Chemical Senses organ
32. Male reproductive anatomy and physiology
33. Female reproductive anatomy and physiology
34. Histology Histotechnics. Cytology.
35. Embryonic development of mammals and humans.
36. Epithelium tissue.Glands.
37. Blood and lymph
38. Connective tissues.
39. Muscle tissue.
40. Nervous tissue.

### Learning outcomes

Students on the final written and test exam must demonstrate in their responses the ability to:

- describe and identify the structural and organizational structure of internal organs, localize and describe, correctly using the appropriate terminology, on models, drugs and medical imaging materials, the typical structure of internal organs and systems of human organs in the normal way, taking into account age, gender and individual characteristics;
- understand the functional organization of the human body at the systemic and organ level, the physiological processes of excitable tissues;
- explain the relationship of structure and function at the level of tissue, organs and organ systems, and the main physiological mechanisms for maintaining homeostasis, vital activity of the body and their features, taking into account age, gender and individual differences;
- integrate knowledge about the structure of the 12 organ systems at the systemic, organ levels and their phylogenetic development to understand anatomical and physiological features in different periods of normal development;

### A rough typology of tasks for the exam

#### To pass the exam in writing

№	Lesson topics	Exam question
<b>1</b>	<p><b>Introduction:</b></p> <ul style="list-style-type: none"> <li>- <i>Introduction to anatomy of physiology.</i></li> <li>- <i>Homeostasis, negative feedback, positive feedback,</i></li> <li>- <i>Anatomical position, Anatomical planes, directional terms. Main areas of the body (axial and appendicular region), body cavities and membranes, organ systems</i></li> </ul>	<p><i>Demonstrate the anatomical position.</i></p> <p><i>Describe the human body using directional and regional terms.</i></p> <p><i>Identify three planes, most commonly used in the study of anatomy</i></p> <p><i>Distinguish between the posterior (dorsal) and the anterior (ventral) body cavities, identifying their subdivisions and representative organs found in each</i></p> <p><i>Describe serous membrane and explain its function</i></p> <p><i>Define homeostasis and explain why this concept is central to physiology;</i></p> <p><i>Define negative feedback, give an example of it, and explain its importance to homeostasis;</i></p>

		<p><i>Define positive feedback and give examples of its beneficial and harmful effects</i></p> <p><i>Define gradient, describe the variety of gradients in human physiology, and identify some forms of matter and energy that flow down gradients</i></p>
2	<p><b>Integumentary system.</b></p> <ul style="list-style-type: none"> <li>- <i>Skin structure and function.</i></li> <li>- <i>General skin signs.</i></li> <li>- <i>The structure and function of the skin glands</i></li> <li>- <i>Skin blood circulation.</i></li> </ul>	<p><i>List the functions of the integumentary system and relate them to its structure;</i></p> <p><i>Describe the normal and abnormal colors that the skin can have, and explain their causes;</i></p> <p><i>Describe the common markings of the skin;</i></p> <p><i>Name two types of sweat glands, and relate the structure and function of each;</i></p> <p><i>Describe the location, structure, and function of sebaceous and ceruminous glands; Describe the role of dermal circulation;</i></p>
3	<p><b>Skeletal system:</b></p> <ul style="list-style-type: none"> <li>- <i>Bone Physiology;</i></li> <li>- <i>Bone development.</i></li> <li>- <i>Bones associated with the skull, cranial bones, facial bones.</i></li> <li>- <i>General features of the spine, general structure of the vertebra, intervertebral discs. Characteristics of the vertebrae.</i></li> <li>- <i>Pectoral girdle and upper limb.</i></li> <li>- <i>Pelvic girdle and lower limb..</i></li> </ul>	<p><i>List the functions of the skeletal system and relate them to its structure;</i></p> <p><i>Discuss the role of bones in regulating calcium and phosphate levels in the blood</i></p> <p><i>List the main hormones that regulate bone physiology, describe their action, describe the role of calcium in the skeletal system</i></p> <p><i>Describe two mechanisms of bone formation</i></p> <p><i>Describe the processes by which minerals are added to and removed from bone</i></p> <p><i>Explain why bone count varies by age and individual</i></p> <p><i>Describe the general characteristics of the spine and a typical vertebra;</i></p> <p><i>Describe the structure of the intervertebral discs and their connection with the vertebrae</i></p> <p><i>Identify the vertebrae in different areas of the spine</i></p> <p><i>Identify the sternum and ribs</i></p> <p><i>Identify the features of the clavicle, scapula, humerus, radius, ulna</i></p> <p><i>Describe the common features of tubular bone and flat bone</i></p> <p><i>Identify and describe the features of the pelvic girdle</i></p> <p><i>Compare the anatomy of the male and female pelvic girdles and explain the functional significance of the differences</i></p> <p><i>Identify and describe features of the femur, patella, shin bones, fibula, and foot bones</i></p>
4	<p><b>Joint:</b></p> <ul style="list-style-type: none"> <li>- <i>Joints and their classification.</i></li> <li>- <i>Jaw joints</i></li> <li>- <i>knee joints</i></li> </ul>	<p><i>Explain what joints are, how they are called and what functions they perform</i></p> <p><i>Name and describe the four main categories of joints</i></p> <p><i>Identify and describe the anatomical components of a typical synovial joint</i></p> <p><i>Identify the main anatomical features of the jaw and knee joints</i></p> <p><i>Describe the motion of the jaw, shoulder joints, hip and knee joints, elbow and ankle joints</i></p>

<p><b>5</b></p>	<p><b>Muscle system:</b></p> <ul style="list-style-type: none"> <li>- <i>The Functions of Muscles,</i></li> <li>- <i>The Nerve-Muscle Relationship. Behavior of Skeletal Muscle Fibers</i></li> <li>- <i>Behavior of the whole Muscle. Muscle Metabolism</i></li> <li>- <i>Muscles of the head and neck</i></li> <li>- <i>Muscles of the Anterior Abdominal Wall; Muscles of the Pelvic Floor; Muscles of the Back. Muscles of Respiration. Muscles Acting on the Hip and Femur, Muscles Acting on the Knee and Leg. Muscles Acting on the Foot, Intrinsic Muscles of the Foot</i></li> <li>- <i>Muscles Acting on the Shoulder and Arm; Muscles Acting on the Forearm, the Wrist and Hand</i></li> <li>-</li> </ul>	<p><i>Describe the various functions of muscular system;</i>  <i>Describe the five physiological properties of all muscular tissue and their relevance to muscle function</i>  <i>Distinguish characteristics of skeletal muscle ,cardiac muscle and smooth muscle</i>  <i>Describe the structure of a neuromuscular junction and function of each of its component</i>  <i>Describe the behavior of a skeletal muscle fiber;</i>  <i>Distinguish between isometric and isotonic contraction</i>  <i>Distinguish between erobic respiration and anaerobic fermentation with respect to muscle function</i>  <i>Distinguish between erobic respiration and anaerobic fermentation with respect to muscle function</i>  <i>Describe muscle fatigue and its causes</i>  <i>Distinguish between slow oxidative and fast glycolytic muscle fibers;List the respective advantages of each;</i>  <i>Explain how they relate to the power and recruitment of motor units; and Give examples of muscles in which each type predominates</i>  <i>Describe the physiological properties that all muscle types have in common;</i>  <i>Name (English and Latin) and locate the muscles that produce facial expressions;</i>  <i>Name (English and Latin) and locate the muscles used for chewing and swallowing;</i>  <i>Name (English and Latin) and locate the neck muscles that move the head;</i>  <i>Name (English and Latin) and locate the muscles of respiration and explain how they affect airflow and abdominal pressure;</i>  <i>Name (English and Latin) and locate the muscles of the abdominal wall, back, and pelvic floor;</i>  <i>Name (English and Latin) and locate the muscles that act on the hip, knee joints;</i>  <i>Name (English and Latin) and locate the muscles that act on the ankle, and toe joints;</i>  <i>Describe the stages of a muscle twitch; Explain how successive muscle twitches can add up to produce stronger muscle contractions;</i></p>
<p><b>6</b></p>	<p><b>Circulatory System: Blood</b></p> <ul style="list-style-type: none"> <li>- <i>Introduction, Blood Types. Erythrocytes. Leukocytes.</i></li> <li>- <i>Platelets and Hemostasis, The Control of Bleeding.</i></li> </ul>	<p><i>Describe the functions and major components of the circulatory system;</i>  <i>Describe the components and physical properties of blood and Explain the significance of blood viscosity and osmolarity;</i>  <i>Explain what determines a person’s ABO and Rh blood types and how this relates to transfusion compatibility;</i>  <i>Describe the effects of a blood type incompatibility between mother and fetus</i></p>

		<p><i>Describe the structure and function of erythrocytes (rbc's); Describe the structure and function of hemoglobin;</i></p> <p><i>Name and describe the types, causes, and effects of erythrocyte excesses and deficiencies</i></p> <p><i>Explain the function of leukocytes in general and the individual role of each leukocyte type;</i></p> <p><i>Discuss the types, causes, and effects of leukocyte excesses and deficiencies.</i></p> <p><i>Describe the body's mechanisms for controlling bleeding and two reaction pathways that produce blood clots ;</i></p> <p><i>List the functions of platelets; Explain what happens to blood clots when they are no longer needed;</i></p>
7	<p><b>Circulatory System: Heart</b></p> <ul style="list-style-type: none"> <li>- Overview of the Cardiovascular System. Gross Anatomy of the heart</li> <li>- Electrical and Contractile Activity of the Heart.</li> <li>- Cardiac Muscle and the Cardiac Conduction System. Blood flow, heart sounds and cardiac cycle</li> <li>- Cardiac Output.</li> </ul>	<p><i>Describe the general location, size, and shape of the heart;</i></p> <p><i>Describe the pericardial sac that encloses the heart.</i></p> <p><i>Describe the three layers of the heart wall;</i></p> <p><i>Identify the four chambers and four valves of the heart, the coronary arteries and their main branches, the major veins that drain the myocardium;</i></p> <p><i>Identify the surface features of the sac heart and correlate them with its internal four-chambered anatomy;</i></p> <p><i>Trace the flow of blood through the four chambers and valves of the heart and adjacent blood vessels;</i></p> <p><i>Describe the components of the cardiac conduction system and the path traveled by electrical signals through the heart;</i></p> <p><i>Definition of cardiac cycle, and the name and explain its four phases</i></p> <p><i>Definition cardiac output (CO); Explain the mechanisms by which sympathetic and parasympathetic nerves raise and lower the heart rate, including the neurotransmitters, receptors, and ions involved</i></p>

<p><b>8</b></p>	<p><b>Circulatory System: Vessels</b>  - Cardiovascular system. General features of the CVS. Blood vessels. Arteries and veins.  Microcirculation stream.  Arterioles. Capillaries. Venules.  - General Anatomy of the Blood Vessels  - Cardiovascular system. Cardiac Muscle muscle tissue. Heart.  Layers of the Heart Wall.  - Blood pressure, resistance and flow  - Capillary Exchange. Regulation of blood pressure and flow.  - Venous Return and Circulatory Shock. Special Circulatory Routes. Anatomy of the Pulmonary Circuit.  - Systemic Vessels of the Axial Region  - Anatomy of the Systemic Vessels of the Appendicular Region  - Anatomy of the Systemic Vessels of the Appendicular Region.</p>	<p><i>Define and distinguish between the pulmonary circuit and systemic circuit from blood pressure, capillary exchange, relative oxygenation of arterial and venous blood, and the vasomotor response to hypoxia</i>  <i>Identify the principal systemic arteries and veins of the axial and appendicular region. Trace the flow of blood from the heart to any major organ of the axial and appendicular region and back to the heart.</i>  <i>Explain How blood flow is related to resistance and pressure differences; the mathematical expression of these relationships</i>  <i>List variables that determine blood pressure and variables that determine peripheral resistance; whether each one is directly or inversely proportional to resistance; and which of them is most changeable from moment to moment</i>  <i>Explain three levels of control over blood pressure and flow</i>  <i>Describe mechanisms of action by angiotensin II, aldosterone, natriuretic peptides, antidiuretic hormone, epinephrine, and norepinephrine on blood pressure</i>  <i>Explain the meaning of capillary exchange and related mechanisms</i>  <i>Expalin venous return and related mechanisms</i>  <i>Distinguish arteries, veins, and capillaries</i>  <i>Classify arteries, veins, and capillaries and describe their structures and functions.</i>  <i>Define baroreflexes, chemoreflexes, and the medullary ischemic reflex</i></p>
<p><b>9</b></p>	<p><b>The lymphatic and immune system:</b>  - Lymphoid system. General features of the Lymphoid system. Thymus. Lymphoid system. Lymph Nodes. Spleen.  The lymphatic and immune system.</p>	<p><i>List the functions of the lymphatic system and relate to the structures;</i>  <i>Explain how lymph forms and returns to the bloodstream;</i>  <i>Name the major cells of the lymphatic system and state their functions;</i>  <i>Describe the structure and function of the red bone marrow, thymus, lymph nodes, tonsils, and spleen</i>  <i>Describe the characteristics of lymphatic capillaries that allow cells and other large particles to enter the lymph</i></p>
<p><b>10</b></p>	<p><b>The Respiratory system</b>  - General Anatomy and physiology of the Respiratory System  - Pulmonary ventilation  Gass exchange</p>	<p><i>List the functions of the respiratory system; Name and describe the organs of respiratory system; Relate the function of any portion of the respiratory tract to its gross and microscopic anatomy</i>  <i>Identify the main structures and Trace the flow of air from the nose to the pulmonary alveoli;</i>  <i>Identify the sources of resistance to airflow and discuss their relevance to respiration;</i>  <i>Explain the significance of anatomical dead space to alveolar ventilation;</i>  <i>Define the clinical measurements of pulmonary volume and capacity;</i></p>

		<p><i>Define terms for various deviations from the normal pattern of breathing.</i></p> <p><i>Define partial pressure and discuss its relationship to a gas mixture such as air;</i></p> <p><i>Contrast the composition of inspired and alveolar air; discuss how partial pressure affects gas transport by the blood;</i></p> <p><i>Describe the mechanisms of transporting O<sub>2</sub> and CO<sub>2</sub>;</i></p> <p><i>Describe the factors that govern gas exchange in the lungs and systemic capillaries; 11.Explain how gas exchange is adjusted to the metabolic needs of different tissues;</i></p> <p><i>Discuss the effect of blood gases and ph on the respiratory rhythm;</i></p> <p><i>Describe the forms and effects of oxygen deficiency and oxygen excess;</i></p> <p><i>Identify and clarify the normal indicators of the intrapulmonary pressures in the lungs;</i></p>
<p><b>11</b></p>	<p><b>The Urinary System</b></p> <ul style="list-style-type: none"> <li>- Functions of the Urinary System.</li> <li>- Anatomy of the Kidney</li> <li>- Urine Formation I: Glomerular Filtration.</li> <li>- Urine Formation II: Tubular Reabsorption and Secretion.</li> </ul> <p>Water concentration</p>	<p><i>Name and locate the organs of the urinary system;</i></p> <p><i>List several functions of the kidneys in addition to urine formation;</i></p> <p><i>Describe the location and general appearance of the kidneys; Identify the external and internal features of the kidney;</i></p> <p><i>Trace the flow of blood through the kidney;</i></p> <p><i>Explain Four basic stages of urine formation and related mechanism regulated each .</i></p> <p><i>Describe the nerve supply to the kidney.</i></p> <p><i>Describe the process by which the kidney filters the blood plasma, including the relevant cellular structure of the glomerulus;</i></p> <p><i>Explain the forces that promote and oppose filtration, and calculate the filtration pressure if given the magnitude of these forces;</i></p> <p><i>Describe how the renal tubules reabsorb useful solutes from the glomerular filtrate and return them to the blood;</i></p> <p><i>Describe how the tubules secrete solutes from the blood into the tubular fluid;</i></p> <p><i>Describe how the nephron regulates water excretion.</i></p> <p><i>Explain how the collecting duct and antidiuretic hormone regulate the volume and concentration of urine;</i></p> <p><i>Explain how the kidney maintains an osmotic gradient in the renal medulla that enables the collecting duct to function.</i></p>

<p><b>12</b></p>	<p><b>The digestive system</b></p> <ul style="list-style-type: none"> <li>- <i>General Anatomy and Digestive Processes</i></li> <li>- <i>The Mouth Through Esophagus The Stomach. The Liver, Gallbladder, and Pancreas.</i></li> <li>- <i>Small and large intestine, Nutrition and metabolism</i></li> </ul>	<p><i>List the functions and major physiological processes of the digestive system;</i></p> <p><i>Distinguish between mechanical and chemical digestion;</i></p> <p><i>Identify the basic chemical process that underlies all chemical digestion, Name the major substrates and products of this process;</i></p> <p><i>List and identify the regions of the digestive tract and the accessory organs of the digestive system;</i></p> <p><i>Describe the general nervous and chemical controls over digestive;</i></p> <p><i>Identify the gross anatomy of the digestive tract from the mouth through the large intestine and accessory organs;</i></p> <p><i>Describe the composition and functions of saliva;</i></p> <p><i>Describe the nervous control of salivation and swallowing.</i></p> <p><i>Describe the process and mechanism of Chemical Digestion and Absorption of Lipid ,protein and carbohydrate</i></p> <p><i>Describe Hormones and paracrine secretions that regulate gastrointestinal function; Explain how gastric activity is controlled; the regulatory mechanisms of the cephalic, gastric, and intestinal phases</i></p> <p><i>Explain how Digestive organs protected from its own acid and enzymes</i></p> <p><i>Describe some factors that regulate hunger and satiety;</i></p> <p><i>Define nutrient and list the six major categories of nutrients;</i></p> <p><i>Name the blood lipoproteins, state their functions, and describe how they differ from each other;</i></p> <p><i>Name the major vitamins and minerals required by the body and the general functions they serve.</i></p>
<p><b>13</b></p>	<p><b>Fluid, electrolyte and acid balance</b></p> <ul style="list-style-type: none"> <li>- <i>Fluid Balance</i></li> <li>- <i>Electrolyte Balance</i></li> <li>- <i>Acid Base Balance</i></li> </ul>	<p><i>Name the major fluid compartments;</i></p> <p><i>List the body's sources of water and routes of water loss;</i></p> <p><i>Describe mechanisms of regulating water intake and output;</i></p> <p><i>List the functions of sodium and potassium;</i></p> <p><i>Explain how electrolyte balance is regulated;</i></p> <p><i>Describe three ways the body regulates pH.</i></p>
<p><b>14</b></p>	<p><b>The Nervous system:</b></p> <ul style="list-style-type: none"> <li>- <i>Overview of the Nervous System. Properties of Neurons. Synapses. Neural Integration. Spinal cord. Somatic reflexes.</i></li> <li>- <i>Spinal Nerves</i></li> <li>- <i>Overview of the meninges, ventricles, cerebrospinal fluid and blood supply. Midbrain. Hindbrain. Forebrain.</i></li> </ul>	<p><i>Identify the gross and microscopic structures of spinal cord in the model;</i></p> <p><i>Identify the innervation of the spinal cord's branch;</i></p> <p><i>State the three principal functions of the spinal cord;</i></p> <p><i>Trace the pathways followed by nerve signals traveling up and down the spinal cord.</i></p> <p><i>Describe the anatomy of nerves and ganglia in general;</i></p> <p><i>Describe the attachments of a spinal nerve to the spinal cord;</i></p> <p><i>Trace the branches of a spinal nerve distal to its attachments;</i></p>



	<p>- <i>Integrative functions of the brain</i>  <i>Cranial Nerves</i></p>	<p><i>Name the five plexuses of spinal nerves and describe their general anatomy; Name some major nerves that arise from each plexus;</i>  <i>Explain the relationship of dermatomes the spinal nerves. Define reflex and explain how reflexes differ from other motor actions;</i>  <i>Describe the general components of a typical reflex arc; Explain how the basic types of somatic reflexes function</i>  <i>List the components of the hindbrain and midbrain and their functions and identify them;</i>  <i>Describe the location and functions of the reticular formation.</i>  <i>Name the three major components of the diencephalon and describe their locations and functions;</i>  <i>Identify the five lobes of the cerebrum in the model and their functions;</i>  <i>Describe the three types of tracts in the cerebral white matter;</i>  <i>Describe the location and functions of the basal nuclei and limbic system.</i>  <i>Describe the blood–brain and blood–CSF barriers, and the clinical meaning</i>  <i>Name and numbers and classify the 12 pairs of cranial nerves, and their relationships to the brainstem and skull foramina</i></p>
<p><b>15</b></p>	<p><b>Sense organs</b>  - <i>Properties and Types of Sensory Receptors</i>  - <i>The General Senses;</i>  - <i>The Chemical Senses -taste</i></p>	<p><i>Define receptor and sense organ;</i>  <i>List the four kinds of information obtained from sensory receptors</i>  <i>Describe how the nervous system encodes each type; outline three ways of classifying receptors.</i>  <i>List several types of somatosensory receptors;</i>  <i>Describe the projection pathways for the general senses;</i>  <i>Explain the mechanisms of pain and the spinal blocking of pain signals;</i>  <i>Explain how taste receptors are stimulated;</i></p>
<p><b>16</b></p>	<p><b>The Endocrine System</b>  - <i>Overview of the Endocrine System .</i>  - <i>The Hypothalamus and Pituitary Gland .</i>  - <i>Other Endocrine Glands</i>  <i>Hormones and Their Actions</i></p>	<p><i>Define hormone and endocrine system;</i>  <i>Name and identify all organs of the endocrine system;</i>  <i>Contrast endocrine with exocrine glands;</i>  <i>Recognize the standard abbreviations for many hormones;</i>  <i>Describe similarities and differences between the nervous and endocrine systems.</i>  <i>Describe the structure and location of the Hypothalamus and Pituitary Gland and other endocrine glands;</i>  <i>Name the hormones these endocrine glands produce, what stimulates their secretion, and their functions;</i>  <i>Discuss the hormones produced by organs and tissues other than the classical endocrine glands.</i>  <i>Identify the chemical classes to which various hormones belong;</i></p>

		<p><i>Explain how target cells regulate their sensitivity to circulating hormones;</i></p> <p><i>Expalin the actions of growth hormone (GH) and the role of insulin-like growth factors in its effects</i></p>
<b>17</b>	<p><b>The Reproductive System</b></p> <ul style="list-style-type: none"> <li>- <i>Male reproductive anatomy and physiology .</i></li> <li>- <i>Female reproductive anatomy and physiology .</i></li> </ul>	<p><i>Identify the gross anatomy of male and female reproductive system;</i></p> <p><i>Enumerate the functions of the male and female reproductive systems;</i></p> <p><i>Distinguish between the gonads of the two sexes, and between the internal and external genitalia.</i></p> <p><i>Describe the structure and function of the glands and other ac-cessory organs of the female and male reproductive system;</i></p> <p><i>Discuss female and male sexual development from puberty through menopause.</i></p>

### The list of anatomical structures

<b>№</b>	<b>Topic</b>	<b>Anatomical structures</b>
<b>1</b>	<b>Integumentary system</b>	Epidermis
		Dermis
		Subcutaneous tissue
		Apocrine sweat gland
		Merocrine sweat gland
		Touch receptor (Tactile corpuscle)
		Hair shaft
		Hair follicle
		Sebaceous (oil) gland
		Motor nerve fibers
		Lamellar corpuscle (pressure receptor)
Sensory nerve fibers		
<b>2</b>	<b>Skeletal System</b>	<b>Skull</b>
		supraorbital foramen / notch
		supraorbital margin
		glabella
		sella turcica
		optic canal

	superior orbital fissure
	foramen rotundum
	foramen ovale
	foramen spinosum
	foramen lacerum
	medial pterygoid plate
	lateral pterygoid plate
	coronal suture
	sagittal suture
	parietal foramen
	zygomatic process
	mandibular fossa
	mastoid process
	stylomastoid foramen
	internal auditory canal
	carotid canal
	jugular foramen
	foramen magnum
	basilar part
	occipital condyle
	hypoglossal canal
	condylar canal
	external occipital protuberance
	superior nuchal line
	inferior nuchal line
	orbital plate
	superior nasal concha
	middle nasal concha
	crista galli
	infraorbital foramen
	frontal process

	orbital surface
	alveolar process
	palatine process
	maxillary sinus
	mental tubercle
	foramen mentale
	condylar process
	coronoid process
	mandibular notch
	mandibular foramen
	angle of mandible
	mandibular ramus
	body of the hyoid bone
	greater horn
	lesser horn
	Pectoral girdle
	superior margin
	medial margin
	lateral margin
	inferior angle
	superior angle
	spine of the scapula
	supraspinatus fossa
	infraspinatus fossa
	scapular notch
	acromion
	coracoid process
	glenoid cavity
	subscapular fossa
	head of rib
	neck of rib

	costal tubercle
	costal groove
	conoid tubercle
	sternal end
	acromial end
	manubrium
	suprasternal (jugular) notch
	clavicular notch
	sternum body
	sternum angle
	xiphoid process
	<b>Pelvic girdle</b>
	iliac crest
	acetabulum
	superior anterior iliac spine
	iliac fossa
	superior ramus of the pubic bone
	inferior anterior iliac spine
	inferior branch of the pubic bone
	obturator foramen
	ischial ramus
	ischial spine
	large sciatic notch
	superior posterior iliac spine
	auricular surface
	inferior posterior iliac spine
	lesser ischial notch
	ischial tuberosity
	<b>Upper limb</b>
	anatomical neck
	Greater tubercle

	lesser tubercle
	intertubercular sulcus
	deltoid tuberosity
	head of humerus
	lateral epicondyle
	medial epicondyle
	lateral supracondylar crest
	medial supracondylar crest
	olecranon fossa
	radial fossa
	radial tuberosity
	styloid process
	trochlea
	olecranon
	coronoid process
	radial notch
	<b>Lower limb</b>
	fossa of the head
	greater trochanter
	lesser trochanter
	intertrochanteric crest
	intertrochanteric line
	linea aspera
	linea pectinea
	gluteal tuberosity
	medial supracondylar line
	lateral supracondylar line
	medial epicondyle
	lateral epicondyle
	medial condyle
	lateral condyle

	intercondylar fossa
	patellar surface
	popliteal surface
	lateral condyle
	medial condyle
	intercondylar eminence
	tibial tuberosity
	medial malleolus
	head of fibula
	apex of the fibula
	lateral malleolus
	scaphoid bone
	lunate bone
	triangular bone
	pisiform bone
	trapezoid bone
	trapezium bone
	capitate bone
	hamate bone
	metacarpal
	proximal phalanx
	distal phalanx
	middle phalanx
	calcaneus
	talus
	scaphoid bone
	medial sphenoid bone
	intermediate cuneiform bone
	lateral cuneiform bone
	cuboid bone
	<b>Vertebral column</b>

	dens
	foramen transversum
	superior articular facet
	inferior articular facet
	spinous process
	transverse process
	body of the vertebra
	anterior sacral foramen
	median sacral crest
	lateral sacral crest
	posterior sacral foramen
	auricular surface
	promontorium
	superior articular process
	Pedicle
	Lamina
	Vertebral arch
	Vertebral foramen
	Intervertebral disc
	Anterior tubercle
	Intervertebral foramen
	Posterior tubercle
	<b>Joints</b>
	Fibular collateral ligament
	tibial collateral ligament
	anterior cruciate ligament
	posterior cruciate ligament
	Medial meniscus
	Lateral meniscus
	Patellar ligament
	transverse knee ligament



		Sphenomandibular ligament
		Lateral ligament
		Joint capsule
		Stylomandibular ligament
		Synovial membrane
		Inferior joint cavity
		Articular disc
		Joint capsule
		Superior joint cavity
<b>3</b>	<b>Muscular System</b>	Muscles of Head and Neck
		Frontalis
		Orbicularis oculi
		Occipitalis
		Levator palpebrae superioris
		Corrugator supercilii
		Nasalis
		Orbicularis oris
		Levator labii superioris
		Levator anguli oris
		Zygomaticus major
		Zygomaticus minor
		Risorius
		Depressor anguli oris
		Depressor labii inferioris
		Mentalis
		Buccinator
		Platysma
		Genioglossus
		Hyoglossus
		Styloglossus
		Palatoglossus

	Temporalis
	Masseter
	Lateral pterygoid
	Medial pterygoid
	Digastric
	Geniohyoid
	Mylohyoid
	Stylohyoid
	Omohyoid
	Sternohyoid
	Thyrohyoid
	Sternothyroid
	Superior, middle, and inferior pharyngeal constrictors
	Sternocleidomastoid
	Anterior, middle, and posterior scalenes
	Trapezius
	Splenius capitis
	Splenius cervicis
	Semispinalis capitis
	Semispinalis cervicis
	Muscles of Trunk
	Diaphragm
	External intercostals
	Internal intercostals
	Innermost intercostals
	External abdominal oblique
	Internal abdominal oblique
	Transverse abdominal
	Rectus abdominis
	Erector spinae
	Semispinalis thoracis

	Quadratus lumborum
	Multifidus
	Ischiocavernosus
	Bulbospongiosus
	Deep transverse perineal
	Compressor urethrae
	External anal sphincter
	Levator ani
	Muscles Acting on the Upper Limb
	Pectoralis minor
	Serratus anterior
	Trapezius
	Levator scapulae
	Rhomboid minor
	Rhomboid major
	Pectoralis major
	Latissimus dorsi
	Deltoid
	Teres major
	Coracobrachialis
	Supraspinatus
	Infraspinatus
	Teres minor
	Subscapularis
	Brachialis
	Biceps brachii
	Triceps brachii
	Brachioradialis
	Anconeus
	Pronator quadratus
	Pronator teres

	Supinator
	Flexor carpi radialis
	Flexor carpi ulnaris
	Flexor digitorum superficialis
	Palmaris longus
	Flexor digitorum profundus
	Flexor pollicis longus
	Extensor carpi radialis longus
	Extensor carpi radialis brevis
	Extensor digitorum
	Extensor digiti minimi
	Extensor carpi ulnaris
	Abductor pollicis longus
	Extensor pollicis brevis
	Extensor pollicis longus
	Extensor indicis
	Adductor pollicis
	Abductor pollicis brevis
	Flexor pollicis brevis
	Opponens pollicis
	Abductor digiti minimi
	Flexor digiti minimi brevis
	Opponens digiti minimi
	Four dorsal interosseous
	Three palmar interosseous muscles
	Four lumbrical muscles
	Muscles Acting on the Hip and Femur
	Iliacus
	Psoas major
	Tensor fasciae latae
	Gluteus maximus

	Gluteus medius and gluteus minimus
	Gemellus superior
	Gemellus inferior
	Obturator externus
	Obturator internus
	Piriformis
	Quadratus femoris
	Adductor brevis
	Adductor longus
	Adductor magnus
	Gracilis
	Pectineus
	Muscles Acting on the Knee and Leg
	Quadriceps femoris
	Rectus femoris
	Vastus lateralis
	Vastus medialis
	Vastus intermedius
	Sartorius
	Biceps femoris
	Semitendinosus
	Semimembranosus
	Popliteus
	<b>Muscles Acting on the Foot</b>
	Fibularis (peroneus) tertius
	Extensor digitorum longus
	Extensor hallucis longus
	Tibialis anterior
	Gastrocnemius
	Soleus
	Flexor digitorum longus

		Flexor hallucis longus
		Tibialis posterior
		Fibularis brevis
		Fibularis longus
		Extensor digitorum brevis
		Flexor digitorum brevis
		Abductor digiti minimi
		Abductor hallucis
		Quadratus plantae
		Four lumbrical muscles
		Flexor digiti minimi brevis
		Flexor hallucis brevis
		Adductor hallucis
		dorsal interosseous muscles
		plantar interosseous muscles
4	<b>Heart</b>	pericardial cavity
		parietal pericardium
		base of heart
		apex of heart
		superior vena cava
		inferior vena cava
		aortic arch
		pulmonary trunk
		pulmonary arteries
		aorta
		visceral pericardium
		endocardium
		myocardium
		right and left atria
		pectinate muscles

		auricle
		right and left ventricles
		interventricular septum
		fibrous rings (anuli fibrosi)
		coronary (atrioventricular) sulcus
		anterior interventricular sulcus
		posterior interventricular sulcus
		left atrioventricular (AV) valve
		right AV (tricuspid) valve
		papillary muscles
		aortic valve
		pulmonary valve
		tendinous cords (chordae tendineae)
		left coronary artery
		anterior interventricular branch
		circumflex branch
		left marginal branch
		right coronary artery
		right marginal branch
		posterior interventricular branch
		great cardiac vein
		posterior interventricular (middle cardiac) vein,
		left marginal vein
		coronary sinus
5	<b>Blood Vessels</b>	Arteries
		Veins
		Capillaries
		tunica interna (tunica intima)
		endothelium
		tunica media
		tunica externa (tunica adventitia)

	Conducting (elastic or large) arteries
	Distributing (muscular or medium) arteries
	arterioles
	Carotid sinuses
	Muscular venules
	Arteriovenous anastomosis
	superior lobar artery
	inferior lobar arteries
	ascending aorta
	aortic arch
	brachiocephalic trunk
	common carotid arteries
	left subclavian
	descending aorta
	vertebral arteries
	thyrocervical trunks
	costocervical trunks
	external carotid artery
	superior thyroid artery
	lingual artery
	occipital artery
	maxillary artery
	superficial temporal artery
	ophthalmic artery
	anterior cerebral artery
	middle cerebral artery
	basilar artery
	posterior cerebral arteries
	anterior cerebral arteries
	anterior communicating artery
	posterior communicating arteries



	dural venous sinuses
	superior sagittal sinus
	inferior sagittal sinus
	transverse sinuses
	cavernous sinuses
	internal jugular vein
	facial vein
	external jugular vein
	vertebral vein
	aortic hiatus
	Bronchial arteries
	Esophageal arteries.
	Mediastinal arteries
	Posterior intercostal arteries
	Subcostal arteries
	Superior phrenic arteries
	internal thoracic artery
	pericardiophrenic artery
	anterior intercostal arteries
	thoracoacromial trunk
	subscapular artery
	subclavian vein
	brachiocephalic vein
	superior vena cava
	azygos vein
	ascending lumbar vein
	hemiazygos vein
	inferior phrenic arteries
	superior suprarenal arteries
	celiac trunk
	superior mesenteric artery

	renal arteries
	ovarian arteries
	testicular arteries
	lumbar arteries
	median sacral artery
	common iliac arteries
	common hepatic artery
	gastroduodenal artery
	hepatic artery proper
	splenic artery
	left gastro-omental artery
	ileal arteries
	ileocolic artery
	middle colic artery
	sigmoid arteries
	superior rectal artery
	vaginal artery
	obturator artery
	internal pudendal artery
	superior vesical artery
	uterine artery
	iliolumbar artery
	superior gluteal artery
	inferior vena cava
	common iliac veins
	lumbar veins
	ovarian veins
	testicular veins
	renal veins
	suprarenal vein
	hepatic veins

	ascending lumbar veins
	hepatic portal system
	inferior mesenteric vein
	splenic vein
	hepatic portal vein
	cystic vein
	subclavian artery
	axillary artery
	circumflex humeral arteries
	brachial artery
	radial collateral artery
	ulnar collateral artery
	radial artery
	ulnar artery
	interosseous arteries
	palmar arches
	dorsal venous network
	cephalic vein
	basilic vein
	median cubital vein
	median antebrachial vein
	venous palmar arches
	radial veins
	ulnar veins
	brachial veins
	axillary vein
	subclavian vein
	external iliac artery
	femoral artery
	deep femoral artery
	circumflex femoral arteries

		popliteal artery
		anterior tibial artery
		dorsal pedal artery
		arcuate artery
		posterior tibial artery
		lateral plantar arteries
		deep plantar arch
		fibular artery
		dorsal venous arch
		saphenous vein
		deep plantar venous arch
		fibular veins
		popliteal vein
		femoral vein
		common iliac vein
6	<b>Respiratory System</b>	Nasal cavity
		Hard palate
		Nostril
		Pharynx
		Larynx
		Trachea
		Pleural cavity
		Pleura
		Epiglottis
		Posterior nasal aperture
		Soft palate
		Esophagus
		Left lung
		Left main bronchus
		Lobar bronchus
		segmental bronchus

	Diaphragm
	Alar nasal sulcus
	Dorsum nasi
	Nasofacial angle
	Nasal septum
	Nasal bone
	Lateral cartilage
	Minor alar cartilages
	Major alar cartilages
	Septal nasal cartilage
	nasal fossae
	nasal conchae
	nasopharynx
	laryngopharynx
	oropharynx
	Frontal sinus
	Meatuses
	Vestibular fold
	Vocal cord
	Uvula
	Auditory tube
	Cribriform plate
	Vestibule
	Guard hairs
	Upper lip
	Perpendicular plate
	Septal cartilage
	Lingual tonsil
	Sphenoid sinus
	Hyoid bone
	Thyrohyoid ligamen

	Vomer
	Thyroid cartilage
	Laryngeal prominence
	Arytenoid cartilage
	Cricoid cartilage
	Cricotracheal ligament
	Cuneiform cartilage
	Corniculate cartilage
	Fat pad
	Tracheal cartilage
	Glottis
	Main bronchi
	Tracheal mucosa
	Lateral cricoarytenoid muscle
	Base of tongue
	Trachealis muscle
	Hyaline cartilage ring
	Mucosa
	Mucous gland
	Perichondrium
	Chondrocytes
	Goblet cell
	Ciliated cell
	Mucociliary escalator
	Apex of lung
	Superior lobar bronchus
	Horizontal fissure
	Middle lobar bronchus
	Middle lobe
	Inferior lobar bronchus
	Oblique fissure

		Inferior lobe
		Base of lung
		Mediastinal surfaces
		Costal surface
		Cardiac impression
		Diaphragmatic surface
		Visceral pleura
		Parietal pleura
		Pleural cavity
		Alveoli
		Bronchial smooth muscle
		Branches of pulmonary artery
		Bronchiole
		Alveolar sac
		Terminal bronchiol
		Respiratory bronchiole
		Capillary networks around alveoli
		Respiratory membrane
		Shared basement membrane
		Pontine respiratory group (PRG)
		Dorsal respiratory group (DRG)
		Ventral respiratory group (VRG)
7	<b>Urinary System</b>	kidneys
		ureters
		urinary bladder
		urethra
		hilum
		renal fascia
		perirenal fat capsule
		fibrous capsule
		renal sinus

	renal cortex
	renal medulla
	renal columns
	renal pyramids
	renal papilla
	minor calyx
	major calyx
	renal pelvis
	renal artery
	segmental arteries
	interlobar arteries
	arcuate arteries
	cortical radiate arteries
	afferent arterioles
	nephron
	glomerulus
	efferent arteriole
	peritubular capillaries
	cortical radiate veins
	arcuate veins
	interlobar veins
	renal vein
	vasa recta
	renal corpuscle
	glomerular capsule
	podocytes
	capsular space
	renal tubule
	proximal convoluted tubule
	nephron loop
	descending limb



		distal convoluted tubule
		collecting duct
		papillary duct
		juxtamedullary nephrons
		cortical nephron
		renal plexus
		juxtaglomerular apparatus
		detrusor
		external urethral orifice
		urethral glands
		internal urethral sphincter.
8	<b>Nervous system</b>	The medulla oblongata;
		the cerebellum;
		the midbrain;
		the diencephalon;
		the final brain;
		the hindbrain;
		the brain stem;
		the fourth ventricle;
		the roof of the fourth ventricle;
		superior cerebral sail;
		diamond-shaped fossa;
		the upper and lower legs of the cerebellum;
		the median groove;
		facial tubercle;
		triangles of the hyoid and vagus nerves;
		medial elevation;
		the vestibular field;
		brain strips;
		lateral pockets;
		the legs of the brain;

	the intersternal fossa, the posterior perforated substance;
	black substance;
	the roof of the midbrain;
	the base of the leg of the brain;
	water supply of the midbrain, central gray matter;
	the upper cerebellar legs;
	superior cerebral sail;
	triangle triangle;
	the thalamus, its anterior tubercle and pillow;
	medial and upper surfaces, brain strips;
	interthalamic fusion;
	triangles of leashes, leashes, adhesion of leashes;
	the pineal gland;
	medial and lateral cranked bodies;
	visual crossroads;
	optic tracts;
	gray tubercle, funnel, pituitary gland;
	mastoid bodies;
	the third ventricle;
	cervical thickening;
	lumbosacral thickening;
	brain cone;
	terminal thread;
	the front median gap;
	the posterior median sulcus;
	anterior lateral groove;
	posterior lateral groove;
	back intermediate furrow;
	front spine;
	back spine;
	spinal cord node;

		the spinal nerve;
		a segment of the spinal cord;
		the front horn;
		back horn;
		lateral horn;
		lateral intermediate substance, central intermediate substance;
		the central channel;
		the front cord;
		the back cord;
		lateral cord;
		own bundles (anterior, lateral, posterior);
		the posterior spinal cord pathway;
		the anterior spinal cord pathway;
		lateral spinothalamic pathway;
		lateral cortical-spinal (pyramidal) pathway;
		the reticulospinal pathway;
		anterior spinothalamic pathway;
		anterior cortical-spinal (pyramidal) pathway;
		the roof of the spinal cord;
		the reticulo-spinal path;
		the hard membrane of the spinal cord;
		epidural space; arachnoid membrane;
		subarachnoid space;
		the soft membrane of the spinal cord;
		the denticulate ligament.
9	<b>Lymphatic system</b>	lymphatic organs primary and secondary
		Thymus
		lymphatic nodes
		spleen
		bone marrow

		lymphatic vessels
		lymphatic trunks
		lymphatic ducts
10	<b>Digestive system</b>	Oral cavity
		Parotid gland
		Tongue
		Teeth
		Sublingual gland
		Submandibular gland
		Esophagus
		Pharynx
		Pancreas
		Stomach
		Liver
		Gallbladder
		Bile duct
		Ascending colon
		Transverse colon
		Descending colon
		Sigmoid colon
		Rectum
		Anal canal
		Anus
		Cecum
		Appendix
		Greater omentum
		Lesser omentum
		Mesocolon
		Mesentery
		Vestibule
		Palatoglossal arch

	Palatopharyngeal arch
	Palatine tonsil
	Lingual frenulum
	Superior labial frenulum
	Uvula of soft palate
	Lingual tonsils
	Vallate papillae
	Epiglottis
	Central incisor
	Lateral incisor
	Canine
	premolar
	molar
	Fundic region
	Cardial part
	Gastric rugae
	Greater curvature
	Greater omentum
	Lesser omentum
	Lesser curvature
	Antrum
	Pyloric canal
	Pylorus
	Pyloric sphincter
	Hepatic portal vein
	Hepatic artery proper
	Bile duct
	Quadrangle lobe
	Gallbladder
	Bare area
	Falciform ligament

		Cystic duct
		Hepatopancreatic sphincter
		Hepatopancreatic ampulla
11	<b>Endocrine system</b>	Pineal gland
		Hypothalamus
		Thyroid gland
		Thymus
		Adrenal gland
		Parathyroid glands
		Pancreas
		Pituitary gland
		Testis
		Ovary
12	<b>Reproductive system</b>	Prepuce
		Glans
		Median septum of scrotum
		Cremaster
		Dartos
		Spermatic cord
		Testicular artery
		Ductus deferens
		Pampiniform plexus
		Epididymis
		Tunica vaginalis
		Testis
		Efferent ductule
		Rete testis
		Ampulla
		Seminal vesicle
		Ejaculatory duct
		Prostate

	Bulbourethral gland
	Bulbospongiosus muscle
	Membranous urethra
	Deep artery
	Tunica albuginea
	Median septum
	Lacunae
	Dorsal vein
	Dorsal artery
	Dorsal nerve
	Corpus spongiosum
	Corpus cavernosum
	Spongy (penile) urethra
	Corpus spongiosum
	Prostatic urethra
	Frenulum
	External urethral orifice
	Pubic symphysis
	Corpus cavernosum Deep fascia
	Superficial fascia Skin
	Round ligament Uterus
	Urinary bladder
	Clitoris
	Labium majus
	Labium minus
	Round ligament
	Uterine tube Fimbriae
	Ovary
	Cervix of uterus
	Vaginal orifice
	Fimbriae

	Perimetrium
	Myometrium
	Endometrium
	Infundibulum
	Ampulla
	Isthmus
	Infundibulum
	Fimbriae
	Vagina
	Ovarian ligament

### List of histological specimens submitted for examination

1. Golgi apparatus of nerve cells of spinal ganglion. Osmium impregnation. x400, x630
2. Adipose inclusions in the hepatic cell. Osmic- acid safranin x630
3. Human spermatazoa. Hematoxyline x1000
4. Oocyte of mammal. Hematoxyline-eosin x630
5. Low columnar epithelium of the renal tubules. Hematoxylin-eosin x400
6. Multi-rowed ciliated (pseudostratified) epithelium; Hematoxylin-eosin x400
7. Stratified squamous non-keratinized epithelium; Hematoxylin-eosin x 400
8. Stratified squamous keratinized epithelium; Hematoxylin-eosin x40, x400
9. Human blood smear. Romanovsky-Giemsa. Erythrocyte, Segmented neutrophils, eosinophil, basophil, lymphocyte, Monocyte. Romanovsky-Giemsa x1000
10. Loose irregular fibrous connective tissue; Macrophages. Fibroblasts. Iron- hematoxylin x100, x400, x630
11. Tendon longitudinal section; Hematoxylin-eosin x100, x400
12. Hyaline cartilage. Hematoxylin-eosin x100, x200;
13. Lamellar bone tissue. Schmorl. x100, x200, x400
14. Striated skeletal muscle tissue. Iron-hematoxyline x100, x200, x630
15. Smooth muscle of the wall of urinary bladder. Hematoxylin-eosin x400
16. Neurofibres in multipolar neuron

### Example of Test assignment:

1. Compare and contrast the roles of oligodendrocytes and Schwann cells in the nervous system.
  - A) Both produce myelin, but oligodendrocytes are found in the central nervous system while Schwann cells are found in the peripheral nervous system.
  - B) Both are involved in the regeneration of damaged nerve fibers, but oligodendrocytes produce myelin while Schwann cells do not.
  - C) Oligodendrocytes produce myelin in the central nervous system, while Schwann cells produce myelin in the peripheral nervous system and assist in the regeneration of damaged nerve fibers.
  - D) Oligodendrocytes are involved in maintaining homeostasis in the nervous tissue, while Schwann cells form a tight, protective seal called the blood-brain barrier.

### Examples of questions on medical terminology

Write the term denoting the following:

1. Narrowing of the aorta -
2. Destruction of a blood clot -



3. Weakness of muscle -
4. Without nourishment -

**Example of an OSPE stations**

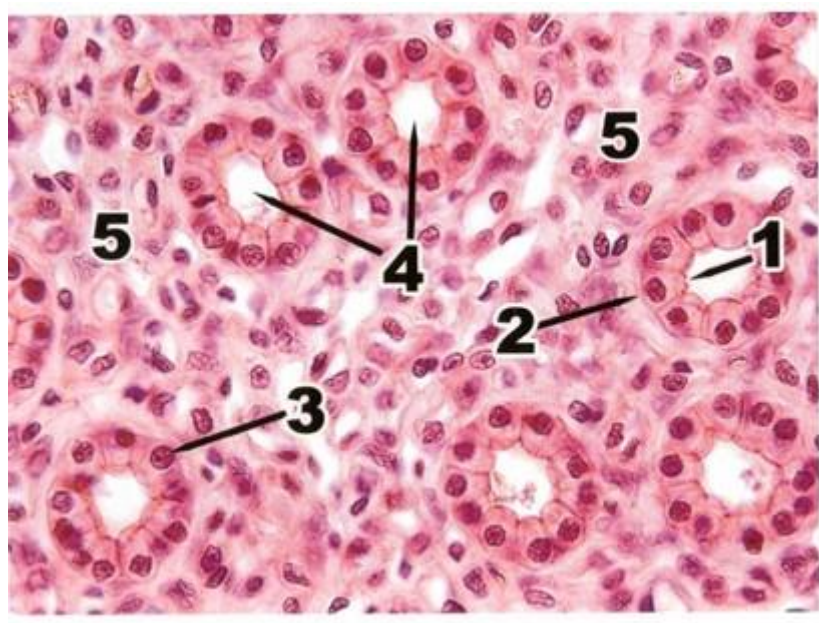
**4 station – the muscles of the lower limbs**

Identify the muscles of the lower extremities listed below on the model. Fill in the empty fields in the table (number, action)

№	Name of the muscle	action
	M. flexor hallucis longus	
	M.gastrocnemius	
	M. gluteus medius	
	M. gracilis	
	M. vastus lateralis	
	M. flexor digitorum brevis	

*Example of histology assignment:*

**Name the structures indicated by numbers. Describe the structure of the epithelium lining the kidney tubules. Compare the structural features of simple and stratified epithelium. Describe the structure of secretory cells. List the classifications of glands**



**Description of microphotography**

<b>Name of the tissue under the microscope</b>	
<b>Individual structural elements (Research objects)</b>	<ol style="list-style-type: none"> <li>1.</li> <li>2.</li> </ol>

	3. 4. 5.
<b>Structural features of this tissue</b>	
<b>Function</b>	

### HISTOLOGY ASSESSMENT CRITERIA

<b>Mark</b>	<b>Criteria</b>	<b>Points</b>
Excellent	<p><b>Assessment of theoretical competence</b> All key aspects are included and presented logically; high accuracy (relevance, no redundancy) and constant attention to the issue; excellent integration of theoretical issues; providing relevant examples; in-depth analysis and theoretical substantiation of this problem, all key aspects are identified and interpreted; fluency in histological terminology. The work is done within the specified time;</p> <p><b>Assessment of practical competence</b> A student absolutely correctly and fully described the histological specimen: a student can distinguish the organ and its staining; properly identified major tissue type from which organ is composed and cellular organization of this structure and listed its function; when describing the histological slide a student demonstrated a competence and logically correct presents his thoughts, correctly used histological terminology; The work is done within the specified time;</p>	<b>100 - 90</b>
Good	<p><b>Assessment of theoretical competence</b> all key aspects are included and presented logically; constant focus on the issue with satisfactory accuracy, relevance; satisfactory integration of theoretical issues; lack of examples; satisfactory analysis and theoretical substantiation of this problem, most of the key aspects are identified and interpreted; correct use of histological terminology; The work is done within the specified time;</p> <p><b>Assessment of practical competence</b> A student make some mistakes when describing the histological slide: partially and uncertainly called the organ and the slide which described; didn't fully describe and didn't identify major tissue type from which organ is composed and cellular organization of this structure and its function; correct use of histological terminology; the work is done within the specified time;</p>	<b>89 - 70</b>
Satisfactory	<p><b>Assessment of theoretical competence</b> Most key aspects included; satisfactory focus on the issue - some errors and / or noticeable redundancy; theoretical problems</p>	<b>69 - 50</b>

	<p>presented without noticeable integration; Providing bad examples or no examples;</p> <p>Some analysis and theoretical substantiation of this problem, most of the key aspects are identified and interpreted; correct use of histological terminology. the work is not done within the specified time;</p> <p><b>Assessment of practical competence</b></p> <p>A student make some mistakes during description the histological slide: couldn't completely name the structures of the organ and its tissues; gets confused when describe the cellular composition of organ's tissues;</p> <p>name their functions; correct use of histological terminology the work is not done within the specified time;</p>	
<p>Unsatisfactory (FX)</p>	<p><b>Assessment of theoretical competence</b></p> <p>Most of the key aspects are missing; lack of attention to the issue - irrelevance and significant redundancy; some theoretical problems presented without integration and understanding; absence or irrelevant examples; some analysis and theoretical substantiation of this problem, most of the key aspects are missing; problems in the use of histological terminology. the work is not done within the specified time.</p> <p><b>Assessment of practical competence</b></p> <p>A student could not identify the histological specimen and didn't distinguish the organ, couldn't identify major tissue type from which organ is composed and cellular organization of this structure and its function, the work is not done within the specified time.</p>	<p><b>49 - 25</b></p>
<p>Unsatisfactory (F)</p>	<p><b>Assessment of theoretical competence</b></p> <p>most or all key aspects are missing; no concentration on the issue, a lot of irrelevant information; significant gaps in theoretical issues, or their superficial consideration; lack of examples or irrelevant examples; no analysis and no theoretical substantiation of the given problem, most of the key aspects are missing; problems in the use of histological terminology the work is not done within the specified time.</p> <p>A student refused to answer; cheated, used copy paste</p> <p><b>Assessment of practical competence</b></p> <p>A student could not identify the histological specimen and didn't distinguish the organ, couldn't identify any tissue type from which organ is composed and cellular organization of this structure and its function.</p> <p>the work is not done within the specified time.</p> <p>A student refused to answer; cheated, used copy paste</p>	<p><b>24 - 0</b></p>

Unsatisfactory (F)	1. most or all of the key aspects are omitted; 2. no focus on the question, not much related to the issue of information; 3. significant gaps in theoretical questions, or their superficial consideration; 4. the lack of examples or irrelevant examples; 5. there is no analysis and no theoretical justification for the given problem (if applicable), most of the key aspects are omitted; 6. problems in using professional terminology	0-24
--------------------	---	------

### Grading system

Rating by letter system	Digital equivalent of points	Percentage	Evaluation using the traditional system
A	4	95-100	Excellent
A-	3,67	90-94	
B+	3,33	85-89	Good
B	3	80-84	
B-	2,67	75-79	
C+	2,33	70-74	
C	2	65-69	Satisfactory
C-	1,67	60-64	
D+	1,33	55-59	
D-	1	50-54	
FX	0	25-49	Unsatisfactory
F	0	0-24	
I (Incomplete)	-	-	«Discipline is not completed» (it is not taken into account when calculating the GPA)

### TEST EXAM:

#### Exam Technology Instructions

1. The duration of the exam is exactly 100 minutes. 100 questions for 100 minutes.
2. Test exams are administered according to the approved schedule.

3. Students may enter the auditorium where the Test exam is administered only with an ID card (Passport or student ID card). The presence of persons not participating in the examination procedure is prohibited.
4. The proctor reconciles the identification document with the admission permission slip. A student who has a discipline clearance rating of less than 50% is not allowed to take the final exam.
5. The proctor (calls the names from the list and sits them down according to the list) starts them in the auditorium.
6. Late students are not allowed to take the exam.
7. Proctor gives each student a question sheet and answer sheet.
8. Students present at the exam must sign the admission form.
9. The start and end times of the test exam are recorded on the blackboard.
10. During the test exam, MCQs on the content are not considered.
11. If the student does not comply with the established requirements at the exam: uses crib notes, mobile and other devices, allows disciplinary violations, disturbs other students with their actions, the proctor has the right to remove students from the audience. In this case, an act of violation of the examination procedure is drawn up, the answer sheet is annulled by crossing out diagonally, the mark "Removed for violation" is made in the admission sheet, "0" points will be given in the sheet.
12. It is allowed for a student to visit the restroom no more than 1 time per hour, lasting no more than 5 minutes. If frequent visits to the restroom are required (for example, due to health conditions), the student must undergo a medical examination, and the exam is counted as the student's absence from the exam.
13. At the end of the exam, the student must turn in a question sheet and answer sheet.

### **Objective Structured Practical Exam (OSPE) Exam Technology Instructions**

1. The duration of the exam is exactly 100 minutes. There will be 10 stations in total, 10 minutes each. At the end of the time, a signal is emitted, students change stations in hourly order.
2. Written examinations are held according to the approved schedule.
3. Students are only allowed to enter the auditorium where the OSPE is held with an identity document (or student ID). The presence of persons not participating in the examination procedure is prohibited.
4. The proctor checks the identity document with the list of admission to the exam. A student with a rating-tolerance in the discipline of less than 50% is not allowed to take the written exam.
5. The launch to the audience is carried out by the proctor (calling names according to the list and seating them according to the list).
6. Late students are not allowed to take the exam.
7. The proctor gives each student a check sheet.
8. Students present at the exam must sign the admission sheet.
9. The start and end times of the written exam are recorded on the blackboard.
10. During the exam, students' questions on the content of checklists are not considered.
11. If a student does not comply with the established requirements for the exam: uses cheat sheets, mobile and other devices, commits disciplinary violations, interferes with other students with his actions, the proctor has the right to remove him from the audience. In this case, an act is drawn up on a violation of the exam procedure, the answer sheet is canceled by crossing out diagonally, the mark "Deleted for violation" is made in the admission sheet, and "0" is affixed to the sheet.
12. Upon completion of the exam, the student must return his checklist.

#### **Basic literature:**

1. Martin Atkinson : Anatomy for dental students. 4-th - edition. (Oxford University Press, 2013)  
ISBN 978-0-19-923446-2
2. Kamran Ali., Elizabeth Prabhakar: Essential Physiology for dental students 1-st edition. (2019 John Wiley & Sons Ltd). ISBN 9781119271758 (ePub) | ISBN 9781119271710 (pbk.)
3. Eric W.Baker., Michael Schuenke, Hugo Zeberg., Anatomy for dental students., 2016 by Thieme Medical Publishers, Inc.

4. Indu Khurana : Human physiology for dental students., 2-nd edition., 2013 . ISBN:978-81-312—3323-8

**Additional literature:**

6. Costanzo, Linda S.: BRS Physiology. Board Review Series.7 edition. -Wolters Kluwer Health, 2018.- 307p. - ISBN 1496367693, 9781496367693
7. Leslie P. Gartner: Color Atlas and Text of Histology. - 7th Edition. - Wolters Kluwer, 2017. ISBN 1496346734, 9781496346735
8. Russell K. Hobbie, Bradley J. Roth: Intermediate Physics for Medicine and Biology. - Springer, 2015. - ISBN 3319126822, 9783319126821
9. Andersson D, Medical Terminology: The Best and Most Effective Way to Memorize, Pronounce and Understand Medical Terms: Second Edition, ISBN-13 : 978-1519066626, 2016
10. Standring, Susan: Gray's Anatomy: The Anatomical Basis of Clinical Practice. - 41 Elsevier Limited, 2016
11. Elaine N. Marieb, Lori A. Smith: Human Anatomy & Physiology Laboratory Manual, Main Version. - 11 edition. - Pearson Education,2015. - ISBN 9780133999143
12. Scanlon V. C, Essentials of Anatomy and Physiology 8th Edition, F.A. Davis Company, 2018
13. Victor P. Eroschenko, Atlas of Histology with Functional Correlations 13th Edition, LWW, 2017
14. William Bialek: Biophysics: Searching for Principles. -Princeton University Press, 2012. - ISBN 0691138915, 9780691138916

**Online resources:**

1. <https://app.lecturio.com/#/>
2. <https://3d4medical.com/>
3. [https://www.youtube.com/channel/UCc\\_I2c2bUtO0p4DVeo6-Kxg](https://www.youtube.com/channel/UCc_I2c2bUtO0p4DVeo6-Kxg)
4. <https://sites.google.com/a/umich.edu/bluelink/curricula/anatomy-403?authuser=0>
5. <https://histologyknmu.wixsite.com/info/gistologicheskie-sajty>
6. <http://www.histology-world.com/contents/contents.htm>
7. <http://www.histologyguide.com/slidebox/02-epithelium.html>
8. <https://histology.medicine.umich.edu/resources>
9. <https://web.duke.edu/histology/>
10. <http://virtualslides.med.umich.edu/Histology/view.apml?listview=1&>